



Provided for noncommercial  
educational use only.

© MedicineToday

# Investigating patients with macrocytosis

In this series, we present authoritative advice on the investigation of a common clinical problem, especially commissioned for family doctors by the Board of Continuing Medical Education of the Royal Australasian College of Physicians.

## KYLIE D. MASON

MB BS

## JEFF SZER

BMedSc, MB BS, FRACP

Dr Mason is an MD candidate at the Walter and Eliza Hall Institute for Medical Research, Melbourne, and was Senior Registrar, Clinical Haematology, Royal Melbourne Hospital.

Dr Szer is Head, Clinical Haematology and Bone Marrow Transplant Service, Royal Melbourne Hospital, Parkville, Vic.

Series Editor

## CHRISTOPHER S.

POKORNY MB BS, FRACP

Dr Pokorny is a member of the Board of Continuing Education, Royal Australasian College of Physicians, and a Gastroenterologist in private practice, Sydney, NSW.

Macrocytosis – an increase in size of erythrocytes – is often associated with anaemia, and is frequently reported on full blood examination where there is an increase in the mean corpuscular volume (MCV) above the upper limit of the normal range (about 95 fL in adults, lower in children). In some patients, this finding may be the first clue to an underlying pathological condition, while in others it may be physiological and of no consequence. In the paediatric population, however, macrocytosis should be considered with some urgency to exclude critical vitamin deficiencies.

### Common causes of macrocytosis

Macrocytosis can be divided into megaloblastic or nonmegaloblastic, with megaloblastosis accounting for approximately 10% of all cases (Table).

Megaloblastic macrocytosis results from a defect in DNA synthesis that causes an imbalance in

erythrocyte precursor cell growth. Cell division is retarded while RNA synthesis is unimpaired, resulting in an increase in the amount of haemoglobin that accumulates in each cell and the formation of a larger erythrocyte.

The most common causes of the impaired DNA synthesis are vitamin B<sub>12</sub> (cobalamin) and folate deficiencies (DNA synthesis requires cyanocobalamin and folate as cofactors). An inadequate dietary intake is a rare cause of vitamin B<sub>12</sub> deficiency but deficiency can result from impaired absorption due to a lack of intrinsic factor in patients who have pernicious anaemia or have had a gastrectomy, or to secondary causes such as bowel bacterial overgrowth, tapeworms or drugs. Folate deficiency may be caused by inadequate dietary intake, the increased requirements of pregnancy, gluten-induced enteropathy, sprue or congenital deficiency. Rather than there being a deficiency, the actions of these vitamins may be

### IN SUMMARY

- Macrocytosis may be the first clue to an underlying pathological condition (such as a haematological, hepatic or thyroid disorder or excess alcohol consumption) in some patients, while in others it may be physiological and of no consequence.
- Macrocytosis is commonly associated with vitamin B<sub>12</sub> and folate deficiency.
- Patients with macrocytosis may be asymptomatic, and the finding is incidental, or they may have symptoms associated with an underlying disorder or deficiency. It is important, therefore, to thoroughly review medication and alcohol use, and consider liver or thyroid disease, gastric or ileal resection and malabsorptive syndromes.
- Blood film examination may lead to the exclusion of factitious causes and focus further investigation, allowing appropriate therapy to be initiated.
- Other investigations include serum vitamin B<sub>12</sub> and folate levels, liver function tests and thyroid stimulating hormone level.

**Table. Causes of macrocytosis****Megaloblastic**

- Vitamin B<sub>12</sub> deficiency or inhibition
- Folate deficiency or inhibition
- Drugs causing defects in DNA synthesis
- Rare congenital syndromes causing defects in DNA synthesis

**Nonmegaloblastic**

- Excessive alcohol consumption
- Hypothyroidism
- Liver disease
- Ineffective haematopoiesis – myelodysplastic syndromes
- Certain other drugs
- Copper deficiency
- Arsenic poisoning
- Congenital dyserythropoietic anaemias

**Factitious**

- Cold agglutinins
- Paraprotein

**Physiological**

- Normal variant
- Response to anaemia of bleeding or haemolysis (polychromasia)

inhibited – for example, nitrous oxide anaesthesia inhibits vitamin B<sub>12</sub> and methotrexate inhibits folate. Certain drugs also impair synthesis (mainly anticancer and immunosuppressive agents such as hydroxyurea, 6-mercaptopurine, azathioprine, methotrexate, cytarabine and 5-fluorouracil), and there are inherited disorders of DNA synthesis.

The abnormality in DNA synthesis affects not only the erythrocytes but also other rapidly growing cells, resulting in characteristic changes in leukocytes (hypersegmentation of nuclei). It also contributes to the neurological changes seen in severe cases of this disease (vitamin B<sub>12</sub>-related neuropathy).

Nonmegaloblastic macrocytosis has a variety of causes, some of which are not immediately apparent. The presence of increased numbers of reticulocytes (which are larger in size than the more mature erythrocytes) can result in an increase in the MCV in patients with either bleeding or haemolysis. This signifies a physiological response to anaemia in the setting of normal haemopoiesis, and is often referred to on a blood film as polychromasia. Alcohol consumption, even relatively small quantities (such as the equivalent of a half bottle of wine per day), causes macrocytosis, and the condition may persist following the cessation of excess intake. Liver disease of any cause, but particularly due to alcohol excess, results in the deposition of excess lipids on the erythrocyte cell membrane, effectively causing an increase in cell size and therefore a rise in the MCV. Severe hypothyroidism may also result in a rise in the MCV.

Drugs are common causes of macrocytosis, with anticonvulsants, anticancer agents, antiretroviral agents and azathioprine all associated. Drugs that affect DNA synthesis can cause macrocytosis with or without megaloblastic changes. Copper deficiency and arsenic poisoning are rare causes of macrocytosis.

Bone marrow disorders as causes of macrocytosis are often associated with quantitative or qualitative changes in the white cells or platelets. Macrocytosis is seen in myelodysplastic syndromes (a frequent cause of macrocytosis in elderly people), aplastic anaemia and pure red cell aplasia.

Physiological causes of macrocytosis are pregnancy and the neonatal period. A factitious rise in the MCV can be caused by the presence of cold agglutinins (as produced in response to infection with *Mycoplasma pneumoniae* or to lymphoma) or by the presence of a paraprotein (as in myeloma). Examination of the blood film is useful in differentiating physiological or factitious macrocytosis from true macrocytosis.

**History and examination**

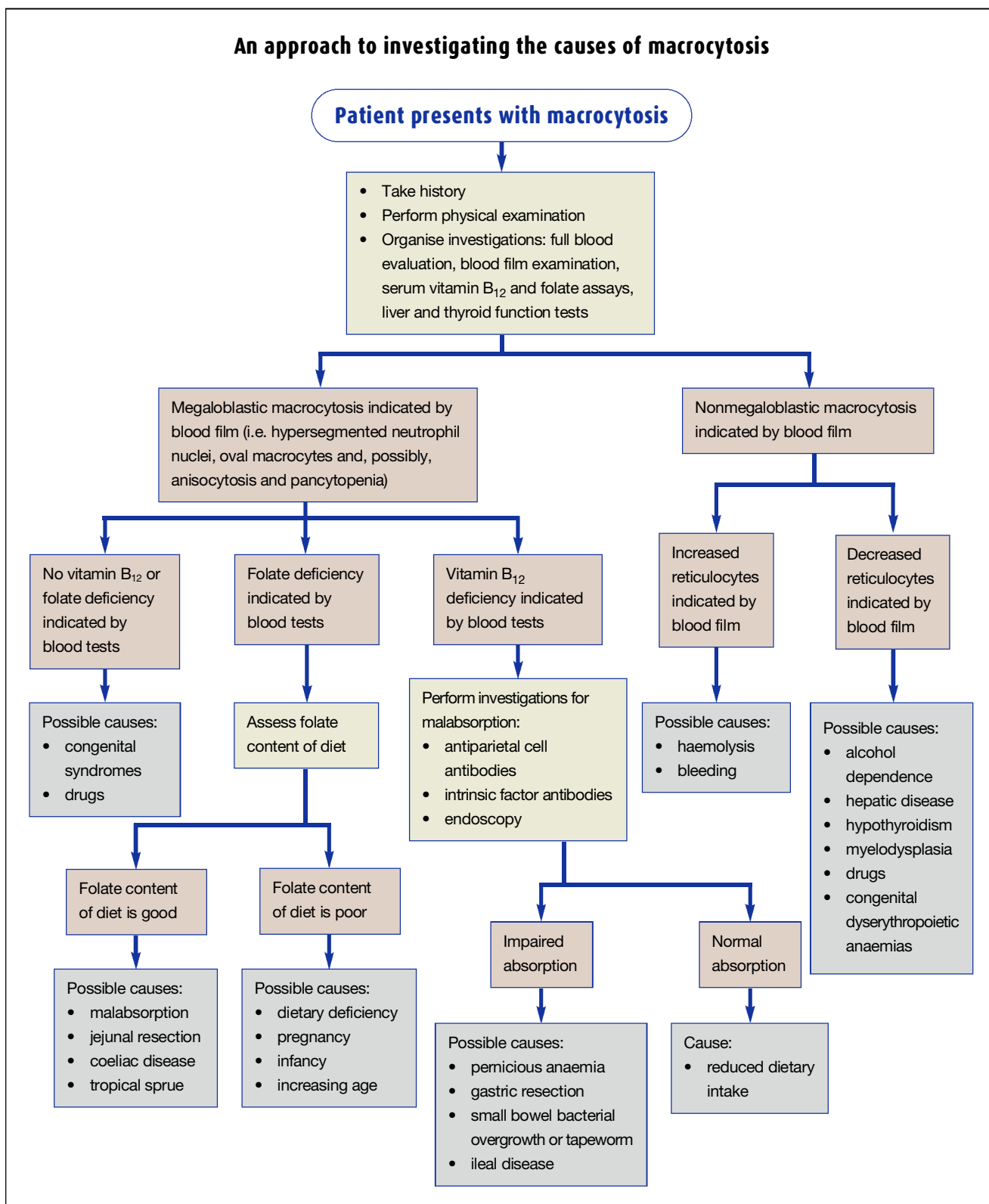
Patients with macrocytosis may be asymptomatic, and the finding is incidental, or they may have symptoms associated with an underlying disorder or deficiency. It is important, therefore, to include a thorough review of medication use (cytotoxic agents may produce a macrocytosis after brief or prolonged exposure, depending on the type of agent and dose used), alcohol use, liver or thyroid disease, gastric or ileal resection, and malabsorptive syndromes. A history relating to haemolysis or bleeding should be sought in patients with a reticulocytosis.

The most common cause of vitamin B<sub>12</sub> deficiency in the Anglo-Saxon population is pernicious anaemia, which is more common in women aged about 60 years with greying hair, blue eyes and blood group A, and in people with a personal or family history of the disease or associated autoimmune diseases. The classic triad of presentation of vitamin B<sub>12</sub> deficiency is weakness, a sore tongue and paraesthesia, but the most common features are those related to the underlying anaemia.

The physical examination of a patient with macrocytosis should concentrate on establishing the aetiology of the condition. Clues include the signs of chronic liver disease (such as jaundice, spider naevi, gynaecomastia, oedema and ascites), the signs of hypothyroidism (such as goitre, oedema and delayed reflexes), and the signs of an underlying malabsorptive syndrome (such as weight loss, cachexia, short stature and, in children, failure to thrive).

It is important to examine for other features of vitamin B<sub>12</sub> or folate deficiency – in particular the vitamin B<sub>12</sub>-associated neuropathy that may occur in the absence of anaemia. This neuropathy is due to symmetrical damage to the peripheral nerves and the posterior and lateral columns of the spinal cord, with the legs generally being more affected than the arms. Folate deficiency may result in a mild peripheral

## An approach to investigating the causes of macrocytosis



continued

neuropathy, or psychiatric changes if severe. A glossitis can be found in both vitamin B<sub>12</sub> and folate deficiencies.

Clinical signs of anaemia, including pallor, may also be present in patients with macrocytosis. In severe cases, there may be signs of congestive cardiac failure.

### Investigations

An approach to investigating the causes of macrocytosis is given in the flowchart on page 37.

#### Full blood count and blood film examination

Examination of the blood film of a patient with macrocytosis gives valuable information regarding the cause of the macrocytosis and can direct further investigations.

Megaloblastosis is suggested by the presence of hypersegmentation (the presence

of five or more nuclear lobes) in neutrophils (Figure 1). Other findings include oval macrocytes, anisocytosis and, in patients with severe vitamin B<sub>12</sub> or folate deficiency, pancytopenia.

The presence of round rather than oval macrocytes and the associated presence of target cells and stomatocytes is suggestive of liver disease and excess alcohol consumption (Figure 2). Spur cells are sometimes seen in advanced liver disease, and haemolysis with spherocytes may be present in acute alcoholic liver disease.

Patients with alcohol dependence alone, with MCV values below 110 fL and little or no anaemia, are most likely to have macrocytosis secondary to alcohol dependence. There are no specific findings to point to other drugs or hypothyroidism as a cause of macrocytosis.

A finding of polychromasia is indicative

of reticulocytosis and suggests haemolysis or bleeding as the cause of the macrocytosis; appropriate investigations should be pursued. The presence of spherocytes, red cell fragmentation or both is highly suggestive of haemolysis (Figure 3). Findings of neutropenia or thrombocytopenia, the presence of circulating blasts, hypogranulated or hypopigmented neutrophils or a leucoerythroblastic blood film may reflect the presence of an underlying bone marrow disorder, and should lead to further investigation with a bone marrow biopsy and referral to a haematologist.

#### Other investigations

Screening of a patient with macrocytosis should also include serum vitamin B<sub>12</sub> and folate evaluations, liver function studies and thyroid stimulating hormone (TSH) levels.

### Macrocytosis: findings on blood film examination

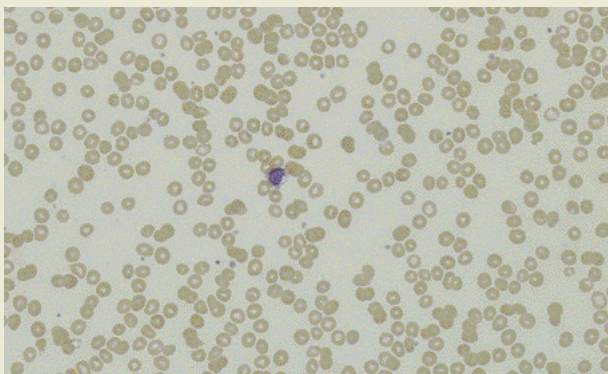
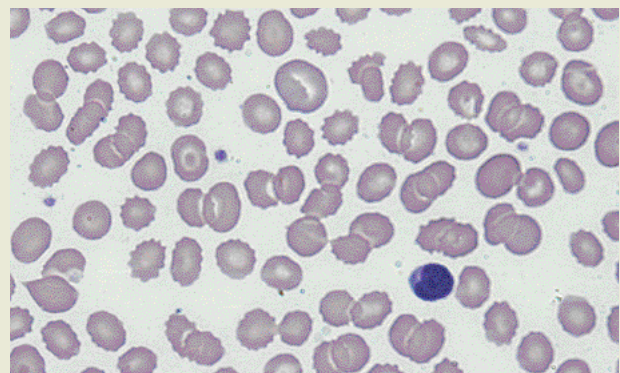
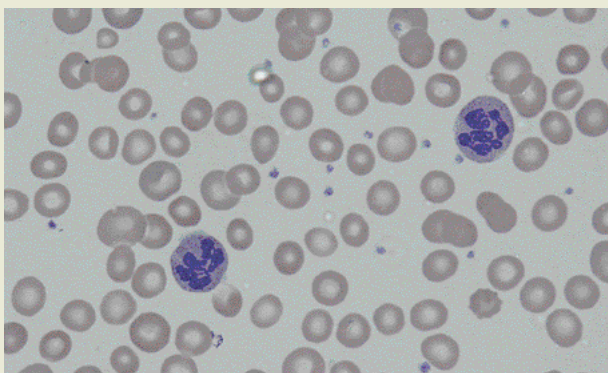


Figure 1 (above left). A blood film showing a neutrophil with hypersegmented nucleus and associated macrocytosis as seen in pernicious anaemia.

Figure 2 (above). A blood film showing many changes of liver disease, including acanthocytes (spiculated red cells), target cells and macrocytes.

Figure 3 (left). A blood film showing variably coloured red blood cells (polychromasia) and spherocytes suggesting a reticulocyte response to haemolysis as the cause of macrocytosis.

---

A low serum concentration of vitamin B<sub>12</sub> or folate implies deficiency, but borderline low levels may suggest a near deficiency, especially with very recent poor dietary intake of folate. Vitamin B<sub>12</sub> levels may be falsely decreased in patients with folate deficiency. The red cell folate level reflects the body folate stores and while a low level implies folate deficiency, the folate concentration will be decreased in vitamin B<sub>12</sub> deficiency and inaccurate in patients who have been recently transfused.

Patients with vitamin B<sub>12</sub> and folate deficiency should be investigated further for an underlying cause. Pernicious anaemia was traditionally identified with the Schilling test, a radioactive vitamin B<sub>12</sub> absorption study that demonstrates the impaired absorption of vitamin B<sub>12</sub>. However, the now near unavailability of bovine intrinsic factor limits the second part of this investigation and the test is not often performed. Pernicious anaemia is now generally diagnosed by blood tests for antiparietal cell antibodies (which are present in 90% of cases) and intrinsic factor antibodies (which are present in 50% of cases), and by endoscopy demonstrating changes

associated with the underlying atrophic gastritis.

Folate deficiency is more commonly associated with dietary deficiency than is vitamin B<sub>12</sub> deficiency and so a dietary history may be of value. Investigation for gluten-induced enteropathy should be considered as this is another cause of folate deficiency. Liver function and thyroid tests should be performed to exclude chronic liver disease and hypothyroidism as causes of macrocytosis.

### Treatment

The goal of therapy is to replace body stores of the deficient vitamin where such a deficiency exists. As folate replacement in a patient with untreated vitamin B<sub>12</sub> deficiency may result in progression of the neurological manifestations of vitamin B<sub>12</sub> deficiency despite a transient improvement in the haematological changes, care should be taken to identify vitamin B<sub>12</sub> deficiency.

Vitamin replacement should be given by the most appropriate route. In folate deficiency, it is often sufficient to supplement the diet with oral folic acid tablets (Blackmores For Women Folic Acid, Megafol, Nature's Own Folic Acid

500 µcg) although there is a parenteral supplement available if required (Folic Acid Injection). In vitamin B<sub>12</sub> deficiency, parenteral supplementation (cyanocobalamin [Blackmores B<sub>12</sub>, Cytamen Injection], hydroxocobalamin [Neo-Cytamen 1000 Injection]) is almost always required, and often for life (as in pernicious anaemia). Improvement in diet may be helpful.

Causes other than vitamin deficiency should be treated as appropriate. Reduction of alcohol intake or discontinuation of an implicated medication may be indicated. Specific therapy for bone marrow disorders may be required, including regular blood transfusions.

### Conclusions

Macrocytosis is commonly associated with vitamin B<sub>12</sub> and folate deficiency but may be indicative of an underlying haematological, hepatic or thyroid disorder or excess alcohol consumption. The examination of a blood film may lead to the exclusion of factitious causes and focus further investigation, allowing appropriate therapy to be initiated. MT

---

DECLARATION OF INTEREST: None.